

Coarctation of the Aorta in Infants under One Year of Age. An Analysis of 20 Years of Experience

Gabriel Lorier, Orlando Wender, Renato A.K. Kalil, Javier Gonzalez, Gustavo Hoppen, Christiano Barcellos, Abud Homsy-Neto, Paulo R. Prates, João R.M. Sant'Anna, Ivo A. Nesralla
Instituto de Cardiologia do Rio Grande do Sul/Fundação Universitária de Cardiologia - Porto Alegre, RS - Brazil

Objective

A review of experience with techniques of correction used, in the last 20 years, in children younger than one year old.

Methods

In the period from 1978 to 1998, 148 patients (pt) with coarctation of the aorta (CoAo), under one year of age, with or without associated intracardiac defects, were submitted to surgery. Median age 50 days, 92 female pt (62.1%). The average weight was $4,367 \pm 1,897$ gr. The average follow-up was $1,152 \pm 1,462$ days. The population was divided in 3 groups: Group I, isolated CoAo: 74 pt (50%); Group II, CoAo and interventricular communication (IVC): 41 pt (27.7%) and Group III, CoAo with complex intracardiac malformations: 33 pt (22.3%).

Results

The total mortality was of 43 patients (29%). In patients younger than 30 days, the mortality was 53%, $p=0.009$, $DR=4.5$, between 31 and 90 days, 14.7%, $p=0.69$, and over 91 days, 15%, $p=0.004$. The probability of actuarial survival of the whole population was 67% at 5 and 10 years. Thirty-six patients (24.3%) had recoarctation, from which 18 patients (50%) were younger than 30 days, $DR=6.35$. The incidence of recoarctation was with Waldhausen technique in 4 patients (10%) and with the classic termino-terminal technique in 19 patients (26%) $p=0.03$, and isthmusplastic operation in 6 patients (37.5%). The patients younger than 30 days showed a relative risk for recoarctation $DR=6.35$. The probability of actuarial survival, free of coarctation repair, at 5 and 10 years was of 69% with Waldhausen's technique and 63% with the classic termino-terminal technique.

Conclusion

Patients younger than 30 days showed increased mortality and recoarctation risk. Waldhausen's technique in patients older than 30 days showed effective. The classic termino-terminal technique did not show to be a good option in all age ranges, being imperative to carry out more radical technical variations, such as the extended termino-terminal.

Key words

heart surgery, aortic coarctation, children

The coarctation of the aorta shows an incidence of 0.2 – 0.6 per 1.000 neonates, representing 5% to 8% of all congenital heart diseases¹.

In 1948, the first successful surgical correction of coarctation of the aorta was performed by Crafoord, in termino-terminal anastomosis.

In 1951, Schumacher² successfully reported a repair of a long segment of coarctation with interposition of subclavian artery and termino-terminal anastomosis.

Vosschuhte, in 1961, published the isthmusplasty operation with graft³. Waldhausen and Nahrwold⁴ modified Shumacher's technique, by introducing the subclavial flap⁵. Since 1961 more than eleven different technical variations have been published. That made inevitable the controversies due to the comparisons of results from the durability of the repairs⁶, but the low number of patients from different publications makes generalized conclusions very difficult. The real proper comparison of operative techniques had not been made yet with scientific strictness⁷, until the early 1990s, when the works by Van Heurn, Conte and Jahangiri⁸⁻¹¹ made a turning point for the analysis for the type of surgical correction in that pathology. At the same time, the anatomicopathological knowledge on the anomalous tissue of the arterial canal and its relations with the aortic isthmus and arch was deepened, as well as the anatomic substratum that allows for the growth of the hypoplastic aortic arch¹¹. Those factors have directly influenced in the choice of the operative technique.

The objective of this paper is to perform a review of our experiences with many aortic coarctation correction techniques, in the last 20 years, in infants under one year of age.

Methods

Retrospective cohort of patients with coarctation of the aorta under one year of age, in which the data were surveyed through a review of clinical records, by following a previously elaborated research protocol.

The aortic coarctation diagnosis was made through clinical examination and echocardiography in all cases.

The surgical indication was due to congestive heart failure or hypertension.

All patients were followed with measurements through Doppler echocardiography, being considered as recurrent coarctation the presence of corrected medium instantaneous gradient of more than 30 mmHg in post-operative in-hospital stay and when such gradient was detected after discharge.

In asymptomatic, normotensive and symmetric pulse patients, a new appointment was scheduled in a month, in which clinical exams, thorax radiography, 12-derivation electrocardiogram and Doppler echocardiogram were carried out. If the results were normal, a clinical appointment was scheduled every six months and echocardiogram once a year. If they were normal after two years, the clinical exams were carried out once a year. If the patient was hypertensive after the surgery or with a pulse deficit, a weekly appointment with clinical exam and echocardiogram, if necessary, was scheduled.

Early mortality was considered when it took place within the first 30 post-operative days. Late mortality was considered after that term.

In the period between June 1978 and December 1998, 148 consecutive patients with coarctation of the aorta, under one year of age, with or without associated intercardial defects, were operated in our Institution.

Age showed a median of 50 days, 55 patients (37.1%) were younger than 30 days, 40 patients (27%) were between 31 and 90 days and 53 patients (35.8%) were over 91 days. Fifty-six patients were male (37.8%), 92 female (62.1%). The average weight was $4,367 \pm 1,729$ grams, and 7.6% weighed less than 2,500 grams. The average follow-up was of $1,152 \pm 1,462$ days.

The population of patients was divided in three groups: Group I, patients with isolated CoAo: 74 patients (50%), Group II, patients with CoAo and interventricular communication (IVC): 41 infants (27.7%) and Group III, patients with CoAo complex intracardial malformations: 33 infants (22.3%).

The three most frequent malformations, in decreasing order, were as follows: patent ductus arteriosus in 95 patients (63.8%), interventricular communication in 41 patients (27.7%) and bicuspid aortic valve in 35 patients (23.6%).

The normal aortic arch was present in 7 patients, from which 5 (71.4%) belonged to Group I; isthmus hypoplasia was present in 103 patients (69.5%), from which 54 belonged to Group I; aortic arch hypoplasia was present in 38 patients (25.6%), 4 (42.9%) of them belonged to Group III. The hypoplasia diagnosis was made in accordance to the echocardiogram operator's criterion and subjective valuation of the surgeon.

Congestive heart failure was present in 52 patients (34.9%), hypertension in 6 patients (4.3%), cyanosis in 25 patients (16.8%). The medications in use before surgery were as follows: digitalis, in 67 patients (45%), diuretics, in 82 patients (55%), vasodilator, in 10 patients (6.7%).

Urgent surgery was performed in 36 patients (24.3%).

In 73 infants (49.3%) classic termino-terminal anastomosis was applied, in 40 infants (27.0%) Waldhausen's technique, in 16 infants (10.8%) isthmoplasty, and in 19 infants (12.8%) other methods (from which, in 87% was Teles de Mendonça's technique¹²). For the performance of termino-terminal technique, simple anastomoses were carried out, and not extended termino-terminal, nor extended radical termino-terminal technique.

The approach of aortic coarctation was done through left-lateroposterior thoracotomy in the fourth intercostal space.

For analgesia at immediate post-operative, all patients out of neonatal period, after surgical correction, were infiltrated with marcaine 0.25% 2 Mg/Kg weight per intercostal space.

The monitoring of average blood pressure was carried out through puncture of the right radial artery.

All continuous variables are described as mean \pm standard deviation. Categorical variables are described in proportions. Simple frequencies were done for all variables.

Data were organized in tables and charts. The associations among categorical variables were tested through the chi-square test, and the continuous variables were tested with Student's t test.

Actuarial survival curves were obtained through the method of Kaplan-Meier.

Finally, logistic regression was carried out, including in the model of all clinically significant variables, in which they had $p < 0.15$ in two-variable analysis. The p - α chosen as statistically significant was equal or less than 0.05.

Results

Total in-hospital deaths occurred in 27 patients, 18.1% (27/148). The average age of those who died was 60.6 ± 15.4 days (the patients who did not evolve to death had an average age of 103 ± 17.2 days, $p=0.2$). The average weight of those who died was $3,455 \pm 786$ g and of those who did not die was $4,549 \pm 654$ g ($p=0.01$).

In Group I, early mortality took place in 9 patients (12.1%) (Group I $n=74$ patients), in Group II, it was in 10 patients (24.3%) (Group II: $n=41$ patients) and in Group III, 8 patients (24.2%) (Group III: $n=33$ patients). Regardless of the group, the patients with aortic arch hypoplasia showed a greater early mortality, $p=0.01$. In patients with aortic arch hypoplasia, in which Teles de Mendonça's technique¹³ and isthmoplasty operation was applied, the mortality was 100% and 60%, respectively.

When Waldhausen's technique was compared with the classic termino-terminal technique, in the presence of aortic arch hypoplasia, there was a significant difference concerning early and total mortality ($p=0.05$).

Total mortality was present in 43 patients (29%).

Infants under 30 days of age increased in 4.5 times the death risk (DR=4.5 CI 95% 1.4-14) $p=0.009$. There was no increase of death risk in other age ranges.

The global mortality in the first quarter of life, relating the 3 surgical techniques currently used in our service, Waldhausen's and termino-terminal techniques were the ones that showed the best results, without significant difference between each other.

The first three intracardiac malformations of greater mortality were, in decreasing order: TGV (66.7%), tricuspid valve anomalies (60%) and left ventricular outflow tract obstructions (50%).

The presence of IVC and complex malformations increased the death risk in 4.1 times (DR=4.1 CI 95% 1.3-12.6) $p=0.01$ and 3.9 times (DR=3.9 CI 95% 1.2-13.2) $p=0.02$, respectively. The presence of aortic arch hypoplasia increased the death risk in 1.9 times (DR=1.9 CI 95% 0.7-5.4) $p=0.19$.

Urgent surgery increased 1.96 times the death risk (CI 95% - 0.87-4.27), which represented an incidence of 32.3% from total deaths.

The actuarial survival probability of the whole population was 67% in 5 and 10 years.

When the population of patients was divided in 2 groups, without and with associated pathologies, the actuarial survival probabilities at 5 years were 81% and 65%, respectively, and at 10 years, they were 81% and 62%, respectively.

Figure 1 shows the actuarial survival probability per surgical tech-



nique. In Waldhausen's technique, the survival was 69% at 5 and 10 years. In classic termino-terminal technique, the survival was 63%, at 5 and 10 years, and in isthmusplasty was 56%, at 5 years.

The actuarial probability of survival in Group I was 82%, at 5 and 10 years, and 68% at 15 years, in Group II it was 52%, at 5 and 10 years, and in group III, 54%, in 5 years.

Regarding the age range, the actuarial curve showed a survival at 5 years of 42% in infants up to 30 days of age. In the ranges of 31 to 90 days and those under 90 days, it was 79% and 85%, respectively (fig. 2).

In 36 patients (24.3%) there was a recoarctation, from which 18 (50%) were under 30 days of age at the moment of the surgery. A new correction was performed in 10 patients (6.8%), with a time median from the first surgery of 53 days; dilation with balloon was carried out in 12 patients (8.1%), with a time median from the surgery of 482 days.

The average age of recoarcted patients was 63.4±12.1 days and 106±27.3 days in patients who were recoarcted, p=0.01. The average weight of the recoarcted patients was 3,908 g and 4,520 g of those who were not recoarcted (p=0.06).

Recoarctations were more frequent in males, 66.7%. Among the females they were 33.3%.

The worst results took place in patients with aortic arch hypoplasia, in which termino-terminal anastomosis was applied, with an incidence of recoarctation of 42%.

Infants up to 90 days, in which the classic termino-terminal

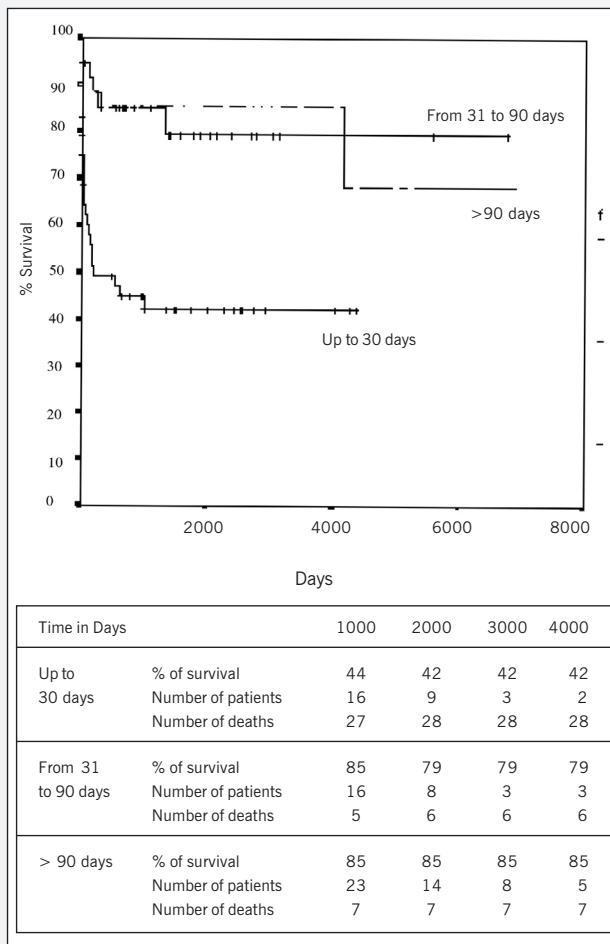


Fig. 2 - Actuarial probability of survival according to age range.

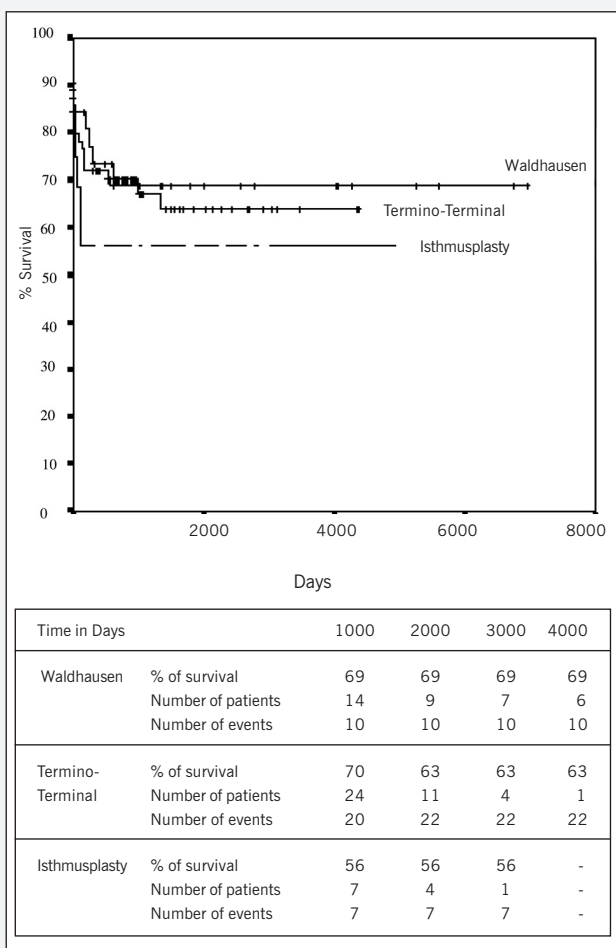


Fig. 1 - Actuarial probability of survival in the whole population.

technique was applied, showed an increase of relative risk of recoarctation of 3.5 times (CI 0.8-13.8) in relation to those within the age range over 90 days, p=0.07. Infants under 30 days showed an increase of 6.3 times of the risk of recoarctation (p=0.01), and the normal aortic arch is shown with reduction of risk for recoarctation. Isthmusplasty increases in 8 times the risk of recoarctation (p=0.0009).

Urgent surgery increased the risk of recoarctation in 1.8 times (CI 95% - 0.8-4.2), 33.3% of the patients who recoarctation had been submitted to urgent surgery.

The actuarial probability free of recoarctation of the whole population at 5 and 10 years was 69% and 40%, respectively. When analyzed regarding the age range, in infants under 30 days it was 60% at 5 years; between 31 and 90 days, it was 64%, at 5 years, and for infants over 91 days, it was 83%, at 5 years (fig. 3).

In the actuarial survival probability free of recoarctation, according to the surgical technique, Waldhausen's technique showed the best results, with 90% and 80% at 5 and 10 years, respectively. (fig. 4).

Analyzing per group of associated malformations, the best results from probability free of recoarctation were shown in Group I (isolated CoAo), 80% at 5 years, 48% at 10 years and 25% at 15 years.

Teles de Mendonça's technique was employed in 13 patients (8.8%), from which 92.3% showed isthmus hypoplasia. The incidence of recoarctation was 38.5% (5 patients).

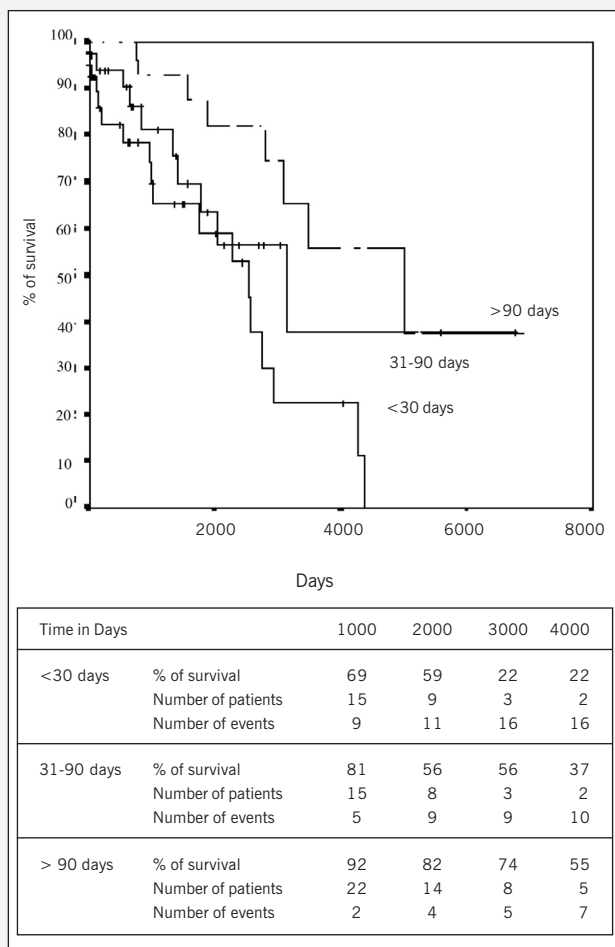


Fig. 3 - Actuarial probability of survival free of repair of coarctation per age range.

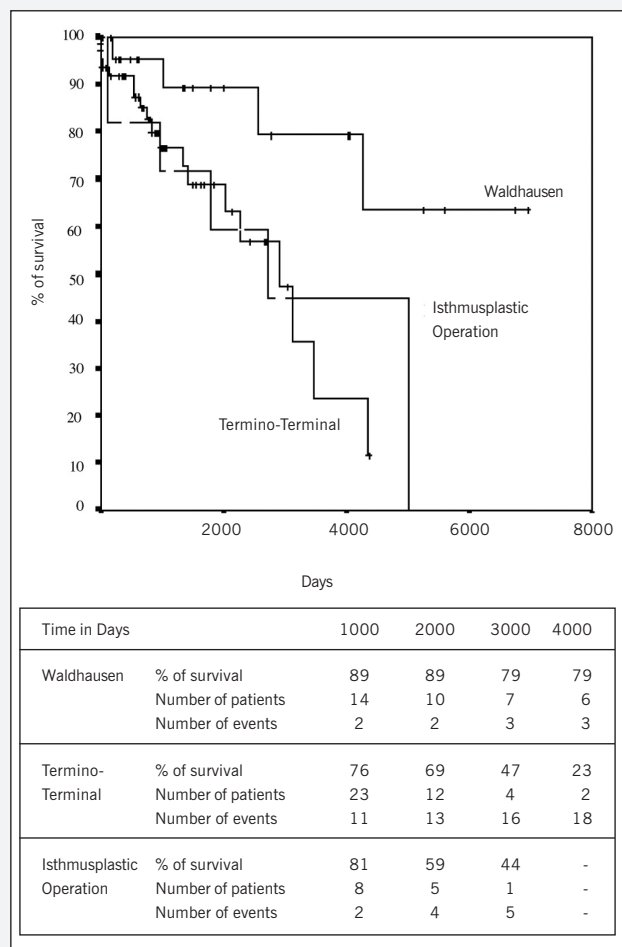


Fig. 4 - Actuarial probability of survival free of repair of coarctation according to surgical technique.

Discussion

Our retrospective cohort showed that Waldhausen's technique – which started in our institution in June 1978¹⁴ – showed the best early and late clinical results.

Some publications have discussed the disadvantages of Waldhausen's technique, such as, for example, the gangrene of the limb, described in 1980¹³, with such complication not being further reported in the literature, or even claudication and hypogrowth^{8,9}, Horner's syndrome⁸, late formation of aneurysms, published 5 cases in the literature¹⁵, being the histopathologic base for its formation the existence of a ductal origin flat muscle that further becomes fibrous¹⁶. Those complications were not found in our series.

In this series, the mortality in infants under 1 year of age with Waldhausen's technique was 25%. In American Consortium of Pediatric Heart Care it was 7.9%, being a multicentric result in the late 1980s¹⁷. When the patients showed hypoplastic aortic arch and isthmus hypoplasia – and the technique of Waldhausen was employed –, the incidence of total mortality was 33.3% and 21.4%, respectively, being such results very high. In infants over 30 days, the results are satisfactory, compared with results from other centers^{8,17-27}.

In our series, the incidence of recoarctation in the first month of life was 25%, regarded as high when compared with the international average²⁵⁻²⁷. The proliferation and constriction of residual canal tissue, still active during the first three months of life¹⁸, can show growth after surgical and be the cause of recoarctation¹⁹.

The incidence of recoarctation, in 8 different papers with a total of 406 patients with up to a month of life, showed the average of recoarctation of 13,3%. However, in the age range of up to 3 months, the incidence lowered to 15%, and, under than 1 year of age, it was 10%, similar results to those found in the literature^{8,19}. We believe, as a cause factor, in the insufficient resection of the ring of the anomalous tissue of the canal, associated to other series of factors. Our actuarial survival free of recoarctation, at 5 years, was 89%. Van Heurn⁸ reports 57%, with Waldhausen's technique (fig. 4).

When we analyze our results with classic termino-terminal technique and compare them with Waldhausen's, we find lower results in all age ranges, concerning the mortality and recoarctation in classic termino-terminal technique, and with those results being similar to those from other publications^{6,27}. The total mortality with classic termino-terminal technique was 29.2%. In the literature, the results varied from 10% to 43%^{8,18} and are considered as unsatisfactory, which recommends for the performance of more aggressive variations of termino-terminal technique, such as those originally described by Amato, in 1991. In the aortic arch hypoplasia, the mortality was 63.2%, showing to be imperative a more suitable reconstruction of aortic arch with extended and extended radical termino-terminal techniques to improve such results⁸. In patients with aortic arch hypoplasia and isthmus hypoplasia, our incidence of recoarctation was 42.1% and 22%, respectively, conflicting with current concepts that termino-terminal technique should not be employed in such anatomic variants¹⁸. In the age range of up to 30 days, 34.6% of



recoarctation took place. In the same way, in the age range between 31 and 90 days, the incidence of recoarctation of 32%, although high, is similar to those found in other publications^{8,19,23}.

Currently it has been emphasized that the most efficient surgical technique to relieve the obstruction is the extended termino-terminal^{7-9, 28-33}. Such procedure does not have the disadvantages of other repair techniques, such as classic termino-terminal³², Waldhausen²⁰ or isthmoplasty operation with graft³³. Either the classic termino-terminal or Waldhausen's or isthmoplasty operation with graft has shown high incidence recoarctation. Such assertions were confirmed in our series. Some authors^{25,34} use the extended termino-terminal technique when the transverse aortic arch shows an index lower than 0.25 in relation to the descending aorta, which means smaller than 3 mm.

The results published in the literature with the extended termino-terminal technique, in a total of 648 patients less than 3 months, in 6 different papers^{8,9,28,30,35,36}, show an incidence of 9.1% of recoarctation. From those, 332 were under a month of age, with an incidence of recoarctation of 9.3%. In neonatal period, always some level of aortic arch hypoplasia is found in patients with aortic coarctation¹⁸. In the paper by Conte⁹ it was present in 81% of the patients. Van Heurn⁸ reported 25% and 33% of isthmus and transverse arch hypoplasia, respectively. Van Son and Zanini reported 44% and 100%^{3,29}, respectively, of aortic arch hypoplasia in children up to three months of age. Therefore, aortic arch reconstruction in neonatal period seems to be primordial, which reduces the mortality and recoarctation³⁴.

Isthmosubclaviplasty or Teles de Mendonça's technique was

described in 1985¹², Méier, in 1986³⁷, reported 28 cases with good results, in only two patients less than 3 months. Amato²⁴, using the technique in 3 neonates (9, 10 and 14 days), showed 100% of recoarctation, Messmer, in 1991²³, showed 43% of recoarctation (3 patients) with an average age of 2.3 months. Other authors showed high levels of recoarctation³⁸. In our series it was employed in 13 patients: 12 with isthmus hypoplasia, showing 16.6% of early mortality (2 patients) and 38.5% (5 patients) of recoarctation, in addition to 1 patient with aortic arch hypoplasia that evolved to early death. Currently, such technique is not routinely employed in our service.

Based on those results, it is possible to infer that patients under 30 days of age and those who have aortic arch hypoplasia show increased risk of mortality and recoarctation, regardless of the technique used.

The classic termino-terminal technique showed, in general terms, not being a good option to relieve the obstruction in all age ranges and in all anatomic variations of aortic arch, which makes imperative to perform other more radical technical variations, such as the extended or extended radical termino-terminal technique.

The classic termino-terminal technique and the isthmoplasty showed twice as much death risk than Waldhausen's technique.

Teles de Mendonça's technique and isthmoplasty operation showed poor results, especially in aortic arch hypoplasia.

Walhausen's technique showed unsatisfactory results in the first month of life, with isthmus and aortic arch hypoplasia. In infants over one month of life, with isthmus and aortic arch hypoplasia, it showed effectiveness.

References

- Crafoord C, Nylin G. Congenital coarctation of the aorta and its surgical treatment. *J Thoracic Surg* 1950; 37: 46. *Apud* Backer L, Mavroudis C. *Glenn's Thoracic and Cardiovascular Surgery*. 6th ed. Vol. I. Stamford: Appleton & Lange, 1996; 76: 1243.
- Schumacker Jr HB. Use of subclavian artery in the surgical treatment of the coarctation of the aorta. *Surgical Gynecol Obstet* 1951;93:491-5. *Apud* Rubay JE, Sluysmans TH, Alexandrescu V, Khelif K, Moulin D, Vliers A, Jaumin P, Chalant H. Surgical repair of coarctation of the aorta in infants under one year of age. *J Cardiovasc Surg*. 1992; 33: 216-22.
- Vosschulte K. Surgical correction of coarctation of the aorta by an "isthmoplasty" operation. *Thorax* 1961;16:338 *apud* Castañeda A, Jonas R, Mayer J, Hanley F. *Cardiac Surgery of the Neonate and Infant*. Philadelphia: WA Saunders, 1994; 22: 353.
- Waldhausen JA, Nahrwold DL. Repair of coarctation of the aorta with a subclavian flap. *J Thorac Cardiovasc Surg*. 1966; 51: 532.
- Rubay JE, Sluysmans TH, Alexandrescu V, et al. Surgical repair of coarctation of the aorta in infants under one year of age. *J Cardiovasc Surg*. 1992; 33: 216-22.
- Merril WH, Hoff SJ, Stewart JR, Elkins CC, Graham TP, Bender HW. Operative risk factors and durability of repair of coarctation of the aorta in the neonate. *Ann Thorac Surg*. 1994; 58: 399-403.
- Harlan JL, Doty DB, Brandt III B, Ehrenhaft JL. Coarctation of the aorta in infants. *J Thorac Cardiovasc Surg*. 1984; 88: 1012-19.
- Van Heurn LW, Wong CM, Spiegelhalter DJ, et al. Surgical treatment of aortic coarctation in infants younger than three months: 1985 to 1990. *J Thorac Cardiovasc Surg*. 1994; 107: 74-86.
- Conte S, Lacour-Gayet F, Serraf A, et al. Surgical management of neonatal coarctation. *J Thorac Cardiovasc Surg*. 1995; 109: 663-75.
- Jahangiri M, Shinebourne EA, Zurkowski D, Rigby ML, Redington AN, Lincin C. Subclavia flap angioplasty: does the arch look after itself? *J Thorac Cardiovasc Surg*. 2000; 120: 224-9.
- Machii M, Becker AE. Hypoplastic aortic arch morphology pertinent to growth after surgical correction of aortic coarctation. *Ann Thorac Surg*. 1997; 64: 516-20.
- Mendonça JT, Carvalho MR, Costa RK, Filho EF. Coarctation of the aorta. A new surgical technique. *J Thoracic Cardiovasc Surg*. 1985; 90: 445-7.
- Geiss D, Williams WG, Lindsay WK, Rowe RD. Upper extremity gangrene: a complication of subclavian artery division. *Ann Thorac Surg*. 1980;30:487-9. *Apud* Conte S, Lacour-Gayet F, Serraf A, Sousa-Uva M, Bruniaux J, Touchot A, Plaché C. Surgical management of neonatal coarctation. *J Thorac Cardiovasc Surg*. 1995; 109: 663-75.
- Prates PR, Lucchese FA, Kalil RAK, et al. Correção da coarctação da aorta pela istmoplastia com a artéria subclávia esquerda em pacientes sintomáticos no primeiro ano de vida. *Arq Bras Cardiol*. 1981; 36: 403-6.
- Kino K, Shunji S, Sugawara E, Kohmoto T, Kamada M. Late aneurysm after subclavian flap aortoplasty for coarctation of the aorta. *Ann Thorac Surg*. 1996; 1262-4.
- Jonas RA. Coarctation: Do we need to resect ductal tissue? *Ann Thorac Surg*. 1991; 52: 604-7.
- Norton Jr JB. Coarctation of the aorta. In: *Perspectives in Pediatric Cardiology*. Vol.6. Armonk: Futura Publishing, 1988; 14: 143-58.
- Castañeda A, Jonas R, Mayer J, Hanley H. Aortic coarctation. In: *Cardiac Surgery of the neonate and infant*. Philadelphia: WB Saunders, 1994.
- Cobanoglu A, Teply JF, Grunkmeier GL. Coarctation of the aorta in patients younger than three months. *J Thorac Cardiovasc Surg*. 1985; 89: 128-35.
- Ziemer G, Jonas RA, Perry SB, Freed MD, Castañeda AR. Surgery for coarctation of the aorta in the neonate. *Circulation*. 1986; 74(Suppl.1): I-25.
- Sanchez GR, Balsara RK, Dunn JM, Mehta AV, O'Riordan AC. Recurrent obstruction after subclavian flap repair of coarctation of the aorta in infants. *J Thorac Cardiovasc Surg*. 1986; 91: 738-46.
- Milliken JC, Braun WJ, Mee RB. Neonatal coarctation: Clinical spectrum and improved results. *J Am Coll Cardiol* 1990;15:78A. *Apud* Backer L, Mavroudis C. *Glenn's thoracic and cardiovascular surgery*. 6^o ed. Vol. I. Stamford: Appleton & Lange, 1996
- Messmer BJ, Minale C, Mühler EV, Bernuth G. Surgical correction of coarctation of coarctation in early infancy; does surgical technique influence the result? *Ann Thorac Surg* 1991;52:594-603. *Apud* Amato JJ, Galdieri RJ, Cotroneo JV. Role of extended aortoplasty related to the definitions of coarctation of the aorta. *Ann Thorac Surg*. 1991; 52: 615-20.
- Amato JJ, Galdieri RJ, Cotroneo JV. Role of extended aortoplasty related to the definitions of coarctation of the aorta. *Ann Thorac Surg*. 1991; 52: 615-20.
- Knott-Craig C, Elkins RC, Ward KE, et al. Neonatal coarctation repair - Influence of technique on late results. *Circulation*. 1993; 99(part 2): 198-204.
- Quaegebeur JM, Jonas RA, Weinberg AD, Blackstone EH, Kirklin JW, and Congenital Heart Surgeons Society. Outcomes in seriously ill neonates with coarctation of the aorta. *J Thorac Cardiovasc Surg*. 1994;108: 841-54.
- Zehr KJ, Gillinov AM, Redmond JM, et al. Repair of coarctation of the aorta in neonates and infants: a thirty-year experience. *Ann Thorac Surg*. 1995; 59: 33-41.

28. Rubay JE, Sluysmans TH, Alexandrescu V, et al. Surgical repair of coarctation of the aorta in infants under one year of age. *J Cardiovasc Surg.* 1992; 33: 216-22.
29. Zanini L, Gargiulo G, Albanese SB, et al. Aortic coarctation with hypoplastic arch in neonates: a spectrum of anatomic lesions requiring different surgical options. *Ann Thorac Surg.* 1993; 56: 288-94.
30. Vouhé PR, Trinquet F, Lecompte Y, et al. Aortic coarctation with hypoplastic aortic arch. *J Thorac Cardiovasc Surg.* 1988; 96: 557-63.
31. Trinquet F, Vouhé PR, Vernant F, et al. Coarctation of the aorta in infants: Which operation? *Ann Thorac Surg.* 1988; 45: 186-91.
32. Kirklin JW, Barrat-Boyes BG. Coarctation of the aorta and interrupted aortic arch. In: _____. *Cardiac Surgery.* 2^a ed. Londres: Churchill Livingstone, 1993; 34: 1263.
33. Backer CL, Paape K, Zales VR, Weigel TJ, Mavroudis C. Coarctation of the aorta. Repair with polytetrafluoroethylene patch aortoplasty. *Circulation.* 1995; 92(suppl.II): II-132-II-6.
34. Siewers RD, Ettetdgui J, Pahl E, Tallman T, del Nido PJ. Coarctation and hypoplasia of the aortic arch: will the arch grow. *Ann Thorac Surg.* 1991; 52: 608-14.
35. Van Son JAM, Falk V, Schneider P, Smedts F, Mohr FW. Repair of coarctation of the aorta in neonates and young infants. *J Card Surg.* 1997; 12: 139-46.
36. Backer CL, Mavroudis C, Zias EA, Amin Z, Weigel TJ. Repair of coarctation with resection and extended end-to-end anastomosis. *Ann Thorac Surg.* 1998; 66: 1365-71.
37. Meier MA, Lucchese FA, Jazbik W, Nesralla IA, Mendonça JT. A new technique for repair of aortic coarctation. Subclavian flap aortoplasty with preservation of arterial blood flow to the left arm. *J Thorac Cardiovasc Surg.* 1986; 92: 1005-12.
38. Nawa A, Nakayama Y, Teramoto S, Mori K, Dohi T. Coarctation restenosis after isthmusubclavioplasty. A consideration on operative procedure and intraluminal balloon angioplasty. *Chest.* 1989; 95:247-50. *Apud* Amato JJ, Galdieri RJ, Cotroneo JV. Role of extended aortoplasty related to the definitions of coarctation of the aorta. *Ann Thorac Surg.* 1991; 52: 615-20.