



## Intra-arterial Autologous Bone Marrow Mononuclear Cell Transplantation for Acute Ischemic Stroke

Maria Lúcia Furtado de Mendonça, Gabriel R. de Freitas, Suzana Alves da Silva, Aquiles Manfrim, Carlos Henrique Eiras Falcão, Constantino Gonzáles, Charles André, Hans Fernando Rocha Dohmann, Radovan Borojevic, Rosália Mendez Otero  
*Hospital Pró-Cardíaco, Universidade Federal do Rio de Janeiro e Instituto do Milênio de Bioengenharia Tecidual - Rio de Janeiro, RJ - Brazil*

Stroke is the third cause of death and the leading cause of disability in adult subjects. Although stroke mortality has been declining in some countries, stroke morbidity has been increasing due to the aging of population and patients improved survival<sup>1</sup>. Treatment with recombinant tissue plasminogen activator (rtPA) is successful provided if it is administered within 3 hours of symptoms onset<sup>2</sup>, but its use is limited to about 5% of the patients with acute ischemic stroke. Furthermore, no neuroprotective agent has yet been proven effective in human clinical trials. The development of other

therapeutic strategies is, therefore, warranted. The use of stem cells in animal models has led to functional improvement following stroke<sup>3</sup>. Recent publications have shown that bone marrow mononuclear cells (BM-MNC) therapy through intracoronary injection is a safe procedure in patients with acute or chronic ischemic heart disease<sup>4,5</sup>. Based on these preliminary data, there has been growing interest in the study of BM-MNC transplantation for acute ischemic stroke.

We report the first case of intra-arterial autologous BM-MNC transplantation for acute ischemic stroke.

### CASE REPORT

A 54-year-old black woman with history of systemic arterial hypertension and ischemic stroke, and who was on phenytoin therapy, was admitted to the emergency department of another institution six hours after the onset of right hemiparesis and global aphasia. Computed tomography (CT) of the brain showed an acute ischemic lesion in the left middle cerebral artery (MCA) territory.

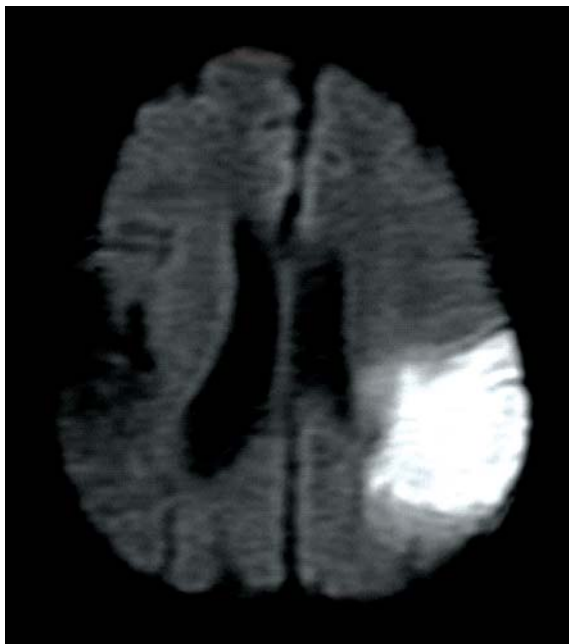Three days following stroke and after the Informed Consent was obtained from her husband and son, the patient was transferred to the Pró-Cardíaco Hospital. At admission, her blood pressure was 110 x 70 mmHg and her heart rate, 85 bpm. Neurological examination showed global aphasia, right faciobrachiorural hemiparesis and hemihypoesthesia with ipsilateral Babinski's sign. Deep reflexes were brisk and symmetrical. The National Institute of Health Stroke Scale (NIHSS), modified Rankin Scale (mRS) and Barthel Index scores were 17, 4, and

5, respectively. Brain magnetic resonance imaging (MRI), including diffusion-weighted imaging, confirmed the presence of a recent lesion in the posterior branch of the left middle cerebral artery and an old lesion in the posterior branch of the right middle cerebral artery (Figure 1) Phenytoin was maintained. Aspirin and low-molecular-weight heparin for prophylaxis of deep venous thrombosis were added to the drug regimen. Routine blood tests were found to be normal. Transcranial Doppler ultrasound (TCD) performed at admission showed patency of intracranial arteries. Electrocardiogram, transthoracic echocardiogram, along with duplex scanning and Doppler color flow imaging of the carotid and vertebral arteries, were all normal.

This patient was selected for the Phase I study protocol "Safety and Feasibility of Autologous Transplantation of Bone Marrow Mononuclear Cells for Acute Ischemic Stroke" previously approved by the Pró-Cardíaco's Research and Ethics Committee and by the National

Committee for Ethics on Research (Comissão Nacional de Ética em Pesquisa - CONEP) on July 30<sup>th</sup>, and filed under the No. CNS/9396.

Diffusion and perfusion MRI obtained on the fourth day before the injection procedure suggested the presence of an ischemic penumbra over part of the left middle cerebral artery territory. Brain single-photon emission computed tomography (SPECT) using Tc-99m showed hypoperfusion in the left parietal and occipital regions (Figure 2A); positron emission tomography with fluorine-18-2-fluoro-2-deoxy-d-glucose (FDG-PET) showed a hypometabolic area within the left parietal lobe and part of the right parietal and occipital lobes (Figure 3A). EEG demonstrated polymorphic delta activity over the left temporal lobe, and TCD revealed normal blood flow velocity in the left MCA.



**Fig. 1** - Diffusion magnetic resonance imaging of the brain performed after symptoms onset showing recent ischemic lesion in the left middle cerebral artery territory and an old lesion in the right middle cerebral artery region

## CELL TRANSPLANTATION

Approximately four hours before the injection procedure, 50 ml of bone marrow were aspirated, under sedation and local anesthesia, from the patient's posterior iliac crest. Bone marrow mononuclear cells were isolated by density gradient using Ficoll-Paque Plus (Amersham Biosciences), washed with heparinized saline containing 5% human serum albumin (HSA) and filtered through a 100- $\mu$ m nylon mesh to remove cell aggregates. These cells were carefully resuspended in normal saline with 5% human serum albumin for injection. A small fraction of cell suspension was used for cell count and viability test by trypan blue exclusion test. Cell viability was > 90%, ensuring cell suspension quality. *Post-hoc* characterization

of cell phenotypes was performed using flow cytometry and functional analysis of a second fraction of cells<sup>6</sup>. In order to determine the presence of mesenchymal progenitor cell lines, fibroblast colony-forming units (CFU-F) were quantified as previously described<sup>6</sup>. All cultures were negative for bacteria and fungi.

The patient was conducted to the interventional cardiovascular laboratory approximately 30 minutes before cell transplantation. After cerebral arteriography and catheterization of the left MCA, about  $30 \times 10^7$  of BM-MNC were injected. No obstruction was found in the left MCA or its branches. A total volume of 3 ml containing  $10 \times 10^7$  of BM-MNC/ml was injected into the MCA in a 10-minute interval. The patient was monitored throughout the procedure by TCD and EEG, which showed no evidence of microembolization (TCD) or electroencephalographic changes (EEG).

## FOLLOW-UP

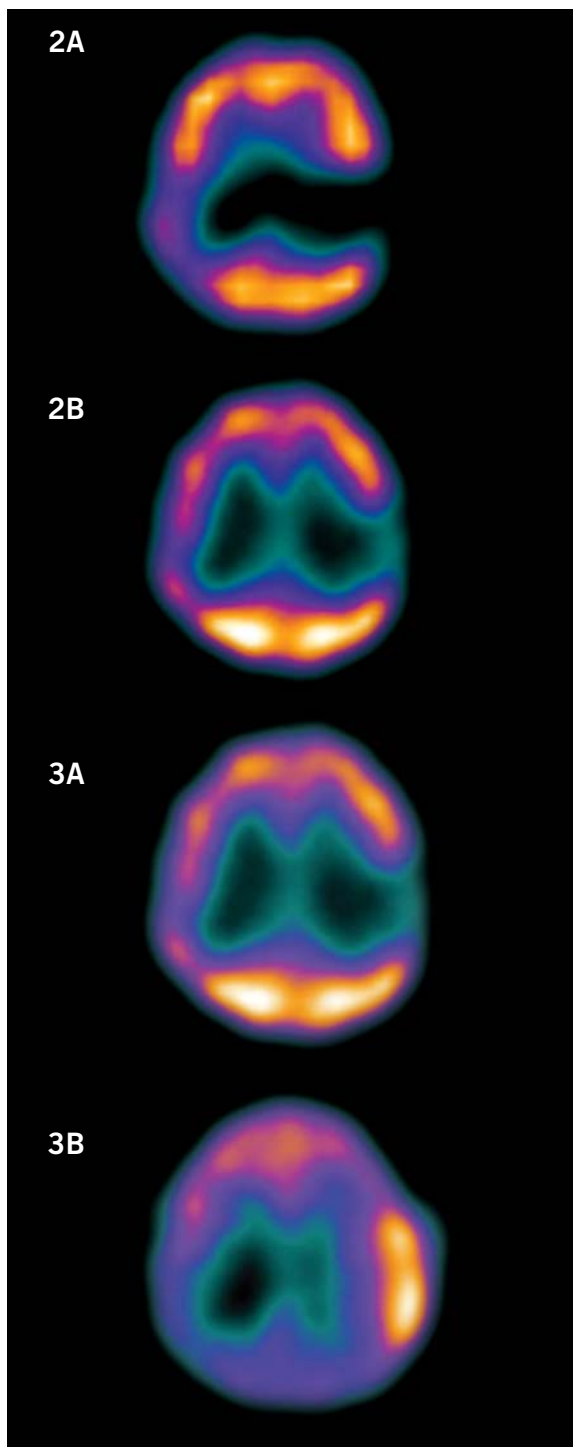
Seven days after transplantation, the patient underwent the same non-invasive complementary examinations performed before the procedure. A slight decrease was found in the ischemic area by MRI diffusion sequence and in hypoperfusion by SPECT (Figure 2B). The FDG-PET showed increased metabolism in the left parietal cortex (Figure 3B). No epileptiform activity was observed on EEG. On neurological examination, the patient showed partial improvement in speech and in the right hemiparesis. She was given gatifloxacin during 10 days for maxillary sinusitis, and quetiapine 12.5 mg was started for insomnia. On the 29th day of follow-up, discharge day, the NIHSS score was 14; the modified Rankin Scale was 3 and the Barthel Index was 60. On the 60th day of follow-up, these scores were 9, 3 and 60, respectively.

## DISCUSSION

This was the first patient enrolled in our Phase I clinical trial "Safety and Feasibility of Autologous Transplantation of Bone Marrow Mononuclear Cells for Acute Ischemic Stroke". The study is intended to include 10 patients in the treatment group and five patients in the control group. This is the very first report of intra-arterial BM-MNC transplantation for acute stroke.

Consistent studies about the use of stem cells for acute stroke were performed in experimental models of focal ischemia<sup>3</sup>. In adult rats submitted to temporary or permanent MCA occlusion, the use of different types of stem cells (mouse bone marrow, human bone marrow, human umbilical cord, etc), either intravenously or intra-arterially, resulted in decreased ischemic area and better functional recovery compared to the control group.

Kondziolka et al<sup>7</sup> studied the safety and feasibility of intraparenchymal transplantation of 2 to  $6 \times 10^6$  neuronal cells derived from human teratocarcinoma in twelve



**Fig. 2A** – Single-photon emission computed tomography performed before bone marrow mononuclear cell infusion, showing hypoperfusion in the left temporal region

**Fig. 2B** – Single-photon emission computed tomography performed after bone marrow mononuclear cell infusion, showing a slight perfusion improvement in the left temporal region

**Fig. 3A** – Positron emission tomography performed just before bone marrow mononuclear cell infusion

**Fig. 3B** – Positron emission tomography performed after bone marrow mononuclear cell infusion shows increased metabolism in the left parietal cortex

patients with basal ganglia stroke and fixed motor deficits. No adverse effects were observed during a 12-month follow-up. The European Stroke Scale score improved in six patients, and six of the eleven PET-scans performed six months after the procedure showed increased FDG uptake at the site of implantation. One patient died of acute myocardial infarction 27 months after transplantation, and pathological studies showed the presence of neurons derived from the transplanted cells<sup>8</sup>.

Stem cells have the ability to self-renew as well as differentiate into multiple cell lines and may be obtained from embryonic, fetal or adult sources. Which is the best source for neuronal repair is still debatable. Autologous adult bone marrow stem cells have some advantages over embryonic stem cells and other kind of cells: there is no risk of rejection and, unlike embryonic cells, they are not associated with teratoma formation or ethical and legal issues.

The mechanism through which the transplanted cells might improve functional recovery remains unknown. It is not clear whether these cells differentiate into neurons or act as small pumps that produce cytokines and trophic factors known to stimulate neurogenesis and angiogenesis<sup>3</sup>. Decreased apoptosis in the ischemic penumbra area has also been proposed<sup>3</sup>. Bone marrow mononuclear cell monitoring using radioactive or magnetic markers may yield further information on the mechanisms of the action of stem cells<sup>10</sup>.

Our Phase I study was designed to evaluate the safety and feasibility of intra-arterial BM-MNC transplantation in patients with ischemic stroke. Therefore, we cannot say whether the favorable clinical outcome or the MRI and PET results are associated with the BM-MNC transplantation or with spontaneous neurological recovery. Either reduced cerebral edema or spontaneous arterial recanalization may be related to the early neurological improvement. Further information about safety will be available after the ten patients have been included in the study.

The use of autologous bone marrow cells for the treatment of stroke is a low-cost, relatively simple, and easy-to-perform option, once its safety and efficacy are proved. Because stroke has an enormous social and economic impact, results in major impairment and suffering for the patient and his family, and the lack of an effective, wide-range treatment, there is a pressing need for multicenter, randomized Phases II and III clinical trials with autologous bone marrow mononuclear cells.

## REFERENCES

---

1. de Freitas GR, Bezerra DC, Maulaz AB, Bogousslavsky J. Stroke: background/epidemiology/aetiology/avoiding recurrence. In: Barnes M, Dobkin B, Bogousslavsky J, eds. *Recovery after Stroke*. Cambridge: Cambridge University Press; 2005. 1-46.
2. The National Institute of Neurological Disorders and Stroke t-PA Stroke Study Group. Tissue plasminogen activator for acute ischemic stroke. *N Engl J Med* 1995; 333: 1581-7.
3. Chopp M, Li Y. Treatment of neural injury with marrow stromal cells. *Lancet Neurol* 2002; 1: 92-100 (Revisão).
4. Perin EC, Dohmann HFR, Borojevic R et al. Transendocardial, autologous bone marrow cell transplantation for severe, chronic ischemic heart failure. *Circulation* 2003; 107: 2294-302.
5. Wollert KC, Meyer GP, Lotz J et al. Intracoronary autologous bone-marrow cell transfer after myocardial infarction: the BOOST randomised controlled clinical trial. *Lancet* 2004; 364: 141-8.
6. Coutinho LH, Gilleece MH, de Wynter EA et al. Clonal and long-term cultures using human bone marrow. In: Testa NG, Molineux G, eds. *Haemopoiesis: A Practical Approach*. New York, NY: Oxford University Press; 1993. 84-5.
7. Kondziolka D, Wechsler L, Goldstein S et al. Transplantation of cultured human neuronal cells for patients with stroke. *Neurology* 2000; 55: 565-9.
8. Nelson PT, Kondziolka D, Wechsler L et al. Clonal human (hNT) neuron grafts for stroke therapy: neuropathology in a patient 27 months after implantation. *Am J Pathol* 2002; 160: 1201-6.
9. Korbli M, Estrov Z. Adult stem cells for tissue repair - a new therapeutic concept? *N Engl J Med* 2003; 349: 570-82 (Revisão).
10. Hofmann M, Wollert KC, Meyer GP et al. Monitoring of bone marrow cell homing into the infarcted human myocardium. *Circulation* 2005; 111: 2198-202.