

## The Importance of Amiodarone Pulmonary Toxicity in the Differential Diagnosis of a Patient with Dyspnea Awaiting a Heart Transplant

Christiano Pereira Silva, Fernando Bacal, Philippe Vieira Pires, Luciano F. Drager, Germano Emílio Conceição Souza, Ginny Michele G. Fajardo, Léa Maria Macruz F. Demarchi, Edimar Alcides Bocchi  
*Instituto do Coração do Hospital das Clínicas – FMUSP - São Paulo, SP - Brazil*

Amiodarone is a class III antiarrhythmic medication used extensively to treat ventricular arrhythmias<sup>1</sup>. It is pharmacologically classified as a cationic amphiphilic drug due to its polar and apolar components. During the past few years, amiodarone has proved to be an effective treatment therapy for patients with ventricular dysfunctions, regardless of the etiology, and in particular ventricular arrhythmia associated with Chagas disease<sup>2</sup>. Nevertheless, despite its hemodynamic and electrophysiological benefits, amiodarone produces serious collateral effects such as a bluish skin discoloration,

photosensitivity, thyroid dysfunction, corneal deposit, peripheral neuropathy, bone marrow suppression, hepatitis, heart blocks, pneumonitis, among others<sup>3</sup>. The objective of this case report is to discuss one of the most serious complications related to amiodarone, pulmonary toxicity, which is described as a differential diagnosis for a chagasic patient that was on the waiting list for a heart transplant. Amiodarone pneumonitis is a relevant differential diagnosis for heart failure (HF) patients using amiodarone that are admitted to the emergency ward with dyspnea.

The correct diagnosis of the etiology of dyspnea in patients with left ventricular dysfunction is decisive for the success of treatment. Several pathologies have to be differentiated from pulmonary congestion under the risk of adopting inadequate procedures. In this case report, the authors approach amiodarone pulmonary toxicity as yet another diagnosis to be investigated especially in patients with Chagasic cardiomyopathy awaiting a heart transplant. The clinical-radiological picture is similar to a picture of decompensated heart failure and the specific use of medication to treat complex arrhythmias contribute to make the correct diagnosis more difficult and therefore make the therapeutic approach more difficult as well.

hospitalization had been three months earlier.

Upon admission at the emergency ward of the Heart Institute (InCor) the patient's general appearance was normal, he had a non-productive cough, dyspnea and fever (37.6°C). There was no previous history of infection, pulmonary disease, ischemia, abuse or incorrect use of medication. Blood pressure was 110 x 60 mmHg, breath sounds were normal with a respiratory rate of eighteen cycles per minute. There were no signs of respiratory failure. The electrocardiogram showed a classic Chagas disease pattern: right bundle block of the His bundle with a left anterior hemiblock. The chest x-ray showed an asymmetrical distribution pattern of bilateral alveolar infiltrates (fig.1).

### CASE REPORT

A 44-year-old male suffering from heart failure for ten years due to a chagasic etiology, had been on the waiting list for a heart transplant for one year. Drug therapy included furosemide (40 mg per day), spironolactone (25 mg per day) and losartan (50 mg per day), as well as amiodarone (400 mg per day), due to a three year episode of sustained ventricular tachycardia. Patient follow-up was conducted on a bi-weekly basis and his condition was classified as functional class III in accordance with the guidelines of the New York Heart Association (NYHA). A radioisotopic ventriculography revealed a left ventricular ejection fraction (LVEF) of 14%, and the patient's last

Treatment for decompensated heart failure was initiated, without improvement in the clinical picture. Ceftriaxone (2 grams per day) was administered for pulmonary infection. There was no improvement with this treatment. A high resolution CT was conducted that showed irregular areas with diffused "dull glass" opacities and interlobular septal thickening. Alterations in the pleura were not identified (fig.2). Arterial blood gas saturation was normal and a pulmonary function test revealed a moderate restrictive disorder. The laboratory tests also revealed a nonspecific increase of leukocytes (12,300/mm<sup>3</sup>), normal lactic acid dehydrogenase (LDH) and a erythrocyte sedimentation rate of 32 mm (normal up to 6 mm). A negative Gallium-67 scintigraphy discarded

### KEY WORDS

Amiodarone, pulmonary toxicity, heart failure.

**Mailing Address:** Christiano Pereira Silva • Rua Charles Spencer Chaplin, 85/21 - 05642-010 – São Paulo, SP - Brazil  
E-mail: chrispsilva@cardiol.br

Received on 04/27/05 • Accepted on 07/01/05

the presence of an active pulmonary inflammatory process, however, despite this finding, the patient was submitted to a transbronchial biopsy that showed non-specific chronic interstitial pneumonia, with moderate inflammatory mononuclear cell infiltrates in the alveolar septum and a large number of macrophages in the alveolar spaces (fig. 3).

These histopathological findings are described as a common pattern for amiodarone induced pulmonary disease<sup>4</sup>. Foamy macrophages are considered a classic sign of amiodarone exposure<sup>4</sup>. Hyaline membranes outlining the alveoli and alveolar spaces, filled with small quantities of erythrocytes and fibrin, were also observed in focal areas. These lesions are found in a small number of patients that develop amiodarone pulmonary toxicity. Foamy cells with relatively small nuclei and clear cytoplasm were observed in the bronchoalveolar lavage (BAL) which are very similar to those found in the BAL fluid of patients with amiodarone pulmonary disease.

These cells are not usually found in the BAL of healthy patients<sup>9</sup>. Bacteria, fungi and bacilli were not shown in appropriate colorations in either the pulmonary biopsy or the BAL.

The amiodarone treatment was immediately interrupted and replaced with prednisone (40 mg per day). After fourteen days of cortisone therapy the patient's clinical and radiological condition improved. After three months of treatment there was a complete resolution of the disease (fig.4), and the patient could once again be placed on the heart transplant waiting list. Sotalol was prescribed as an antiarrhythmic medication and an implantable defibrillator was indicated. Eight months after returning to the waiting list, the patient was transplanted without intercurrents. The transplant surgery was performed more than one year ago, the patient remains asymptomatic and has regular medical follow-up at the InCor heart transplant clinic on a monthly basis.

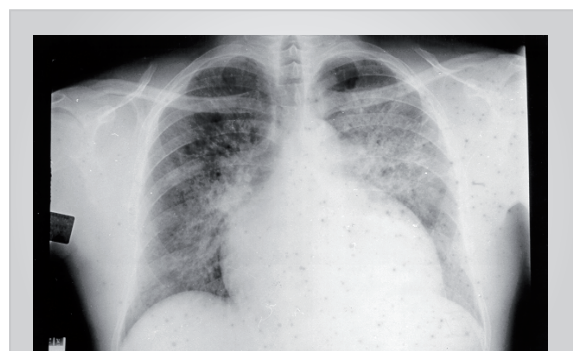


Fig. 1 - Radiografia torácica em projeção pósterio-anterior, mostrando infiltrado intersticial pulmonar bilateral em paciente com aumento global de área cardíaca.

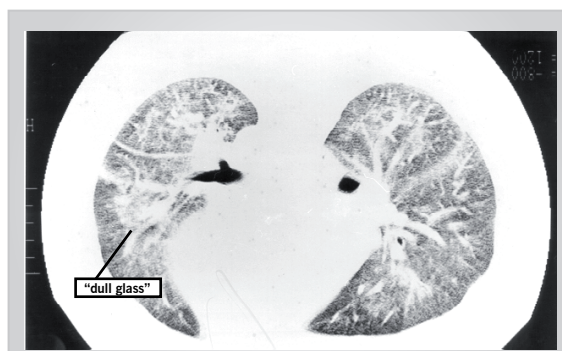


Fig. 2 - Áreas irregulares, opacidade difusa em dull glass, com alargamento dos septos interlobulares e importante infiltrado intersticial difuso, em tomografia computadorizada de alta resolução. Presença de área cardíaca aumentada.

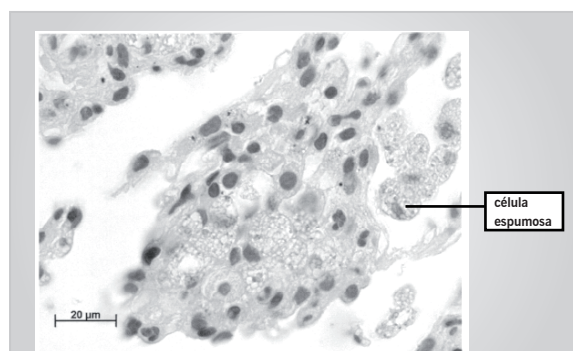


Fig. 3 - Áreas irregulares, opacidade difusa em dull glass, com alargamento dos septos interlobulares e importante infiltrado intersticial difuso, em tomografia computadorizada de alta resolução. Presença de área cardíaca aumentada.

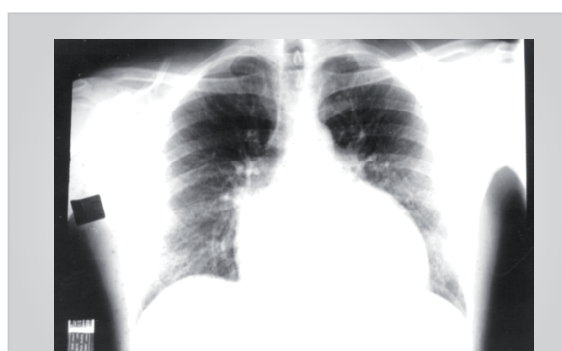

Fig. 4 - Radiografia de tórax em projeção pósterio-anterior, mostrando melhora do padrão pulmonar, com resolução do quadro de infiltração intersticial, com manutenção do significativo aumento da área cardíaca.

## DISCUSSION

Amiodarone toxicity was first described by Rotmensh et al<sup>6</sup> Amiodarone pulmonary toxicity (APT) affects 5% to 7% of patients and has a higher correlation with the total cumulative dose than with the serum level of the drug<sup>7</sup>.

The clinical symptoms can vary from a dry cough and discrete dyspnea to classic respiratory failure however the most common clinical picture is fatigue upon exertion. Associated symptoms such as fever are also common<sup>8</sup>. The appearance of pulmonary masses and nodes is also

reported<sup>9</sup>. Cutaneous vasculitis is rarely present<sup>9</sup>.

APT risk factors include a daily dosage higher than 400 mg (toxic reactions from the drug are more common in patients with amiodarone serum levels higher than 2.5 mg/l), preexisting pulmonary disorder, therapy duration of more than two months, advanced age and previous pulmonary surgery<sup>10</sup>. The occurrence of pulmonary toxicity has also been confirmed in patients using lower dosages of the drug<sup>11</sup>.

The mechanisms involved in APT have not been entirely established. Two hypotheses have been proposed: toxicity directly to the pulmonary cells and an indirect immunological reaction<sup>12</sup>. Patients treated with amiodarone present with different types of pulmonary disease including chronic interstitial pneumonitis (most common), organizing pneumonia (with or without bronchiolitis obliterans), acute respiratory distress syndrome<sup>13</sup>, and solitary pulmonary nodule (rare)<sup>14</sup>.

In this case, APT affected a chagasic patient awaiting a heart transplant. This special situation has serious clinical implications: patients on a transplant waiting list can be called at any time for a surgical procedure, depending on organ availability; the appearance of a pulmonary inflammation could jeopardize a transplant opportunity; conducting this procedure under these conditions raises serious doubts such as the possibility of a worse post-operative prognosis, the appearance of respiratory failure or acute respiratory distress syndrome<sup>15</sup>. In addition, there is not enough information about immunosuppression and infection incidence in these cases.

Another important consideration is the differential diagnosis between this clinical picture and pulmonary congestion secondary to heart failure. Various similar clinical symptoms are present in addition to the chest x-ray. In this case, due to the questionable diagnosis at first, furosemide was administered. The treatment did not improve the clinical or radiological symptoms. It is difficult to differentiate between the two entities and further testing is required to determine the diagnosis. The increase of gallium lung uptake is an important test to detect inflammatory processes such as amiodarone pneumonitis, due to its high sensitivity<sup>16</sup>. Nevertheless, in this case the scintillography was negative. Another accurate radiological exam is the high resolution CT scan, mainly to improve the specificity of nuclear medicine<sup>17</sup>. This test revealed nonspecific alterations that could be related to APT. Since the clinical assumption was almost certain and there were no symptoms that suggested other disorders such as pulmonary embolism or bacterial pneumonia, a

complementary investigation was conducted that included a transbronchial pulmonary biopsy that produced results compatible with amiodarone induced pulmonary damage. The anatomicopathologic study helps to determine the diagnosis and also to define the amiodarone induced pneumonopathy pattern<sup>18</sup>.

Recently, a new diagnostic method has been proposed. Research of KL-6, a high molecular weight mucin glycoprotein that is secreted by pneumocytes, can predict the presence of interstitial pneumonitis, reinforcing the APT diagnosis<sup>19</sup>.

APT treatment for most patients consists in discontinuing the use of amiodarone. Corticosteroid therapy (40 to 60 mg per day of prednisone with a gradual reduction in two to six months) is safe and effective in severe cases and accelerates the resolution process when the simple withdrawal of amiodarone is not sufficient<sup>9</sup>. In patients who develop respiratory failure, inhalation of nitric oxide in conjunction with mechanical ventilator support improves hypoxemia and offers a better prognosis. Nevertheless, approximately 30% of the patients develop irreversible pulmonary fibrosis<sup>20</sup>. Experimental reports demonstrate the effectiveness of vitamin E in the reduction of amiodarone induced pulmonary fibrosis<sup>21</sup>.

Amiodarone is the drug of choice for ventricular arrhythmia treatment in chagasic patients with ventricular dysfunction. Despite the collateral effects demonstrated here, its use is totally justified in this case. New studies have recommended, mainly in the case of ischemia<sup>22</sup>, the use of implantable defibrillators<sup>23</sup> for patients with severe ventricular arrhythmia<sup>24</sup>, syncope or an elevated risk of sudden death<sup>25</sup>. This recommendation is supported by influential clinical studies<sup>26</sup>.

## CONCLUSION

Amiodarone pulmonary toxicity should be considered a differential diagnosis in patients that present with dyspnea in emergency wards. Usually prescribed in high dosages, the drug is widely used and can cause pulmonary toxicity that has a clinical picture very similar to pulmonary congestion. Complementary methods that are more differentiated are useful for the diagnosis of this condition.

### Potencial Conflict of Interest

No potential conflict of interest relevant to this article was reported.

## REFERENCES

1. Mason JW. Amiodarone. *N Eng J Med* 1987; 316: 455-66.
2. Giniger AG, Retyk EO, Laiño RA, Sananes EG, Lapuente AR. Ventricular tachycardia in Chagas' disease. *Am J Cardiol* 1992; 70: 459-62.
3. Chuang CL, Chern MS, Chang SC. *Am J Med Sci*. 2000; 320(1): 64-8.
4. Myers JL, Kennedy JI, Plumb VJ. Amiodarone lung: Pathologic findings in clinically toxic patients. *Hum Pathol* 1987; 18: 349-54.
5. Bedrossian CW, Warren CJ, Ohar J. Amiodarone Pulmonary toxicity: cytopathology, ultrastructure, and immunocytochemistry. *Ann Diagn Pathol* 1997; 1: 47-56.
6. Rotmensch HH, Liron M, Tupilski M. Possible association of pneumonitis with amiodarone therapy. *Am Heart J* 1980; 100: 412-3.
7. Adams GD, Kehoe R, Lesch M, Glassroth J. Amiodarone -induced pneumonitis. Assessment of risk factors and possible risk reduction. *Chest* 1988; 93:254-63.

8. Pollak PT. Clinical organ toxicity of antiarrhythmic compounds: ocular and pulmonary manifestations. *Am J Cardiol* 1999; 84: 37-45.
9. Scharf C, Oechslin EN, Salomon F. Clinical picture: amiodarone-induced pulmonary mass and cutaneous vasculitis. *Lancet* 2001; 358(9298): 2045.
10. Miegheem WV, Coolen L, Malysse I, et al. Amiodarone and the development of ARDS after lung surgery. *Chest* 1994; 105: 1642-45.
11. Ott MC, Khor A, Leventhal JP, Paterick TE, Burger CD. Pulmonary toxicity in patients receiving low-dose amiodarone. *Chest* 2003; 123(2): 646-51.
12. Martin II WJ, Rosenow III EC. Amiodarone pulmonary toxicity. Recognition and pathogenesis (Part II). *Chest* 1988; 93: 1242-8.
13. Ashrafian H, Davey P. Is amiodarone an underrecognized cause of acute respiratory failure in the ICU? *Chest* 2001; 120(1): 275-82.
14. Rodriguez-Garcia JL, Garcia-Nieto JC. Pulmonary mass and multiple lung nodules mimicking a lung neoplasm as amiodarone-induced pulmonary toxicity. *Eur J Intern Med*. 2001; 12 (4): 372-6.
15. Miegheem WV, Coolen L, Malysse I, et al. Amiodarone and the development of ARDS after lung surgery. *Chest* 1994; 105: 1642-45.
16. Dirlik A, Erinc R, Ozcan Z. Technetium-99m-DTPA aerosol scintigraphy in amiodarone induced pulmonary toxicity in comparison with Ga-67 scintigraphy. *Ann Nucl Med* 2002; 16(7): 477-81.
17. Oyama N, Oyama N, Yokoshiki H. Detection of amiodarone-induced pulmonary toxicity in supine and prone positions: high-resolution computed tomography study. *Circ J* 2005; 69(4): 466-70.
18. Conte SC, Pagan V, Murer B. Bronchiolitis obliterans organizing pneumonia secondary to amiodarone: clinical, radiological and histological pattern. *Monaldi Arch Chest Dis* 1997; 52 (1): 24-6.
19. Sangha S, Uber PA, Mehra MR. Difficult cases in heart failure: amiodarone lung injury: another heart failure mimic? *Congest Heart Fail* 2002; 8 (2): 93-6.
20. Donaldson L, Grant IS, Naysmith MR. Acute amiodarone-induced lung toxicity. *Intensive Care Med* 1998; 24: 626-30.
21. Card JW, Racz WJ, Brien JF. Attenuation of amiodarone-induced pulmonary fibrosis by vitamin E is associated with suppression of transforming growth factor-beta1 gene expression but not prevention of mitochondrial dysfunction. *J Pharmacol Exp Ther* 2003; 304 (1): 277-83.
22. Buxton AE, Lee KL, Fisher JD, Josephson ME, Prystowsky EN, Hafley G. A randomized study of the prevention of sudden death in patients with coronary artery disease. Multicenter Unsustained Tachycardia Trial Investigators. *N Engl J Med* 1999; 341: 1882-90.
23. Moss AJ, Hall WJ, Cannom DS, et al. Improved survival with an implanted defibrillator in patients with coronary disease at high risk for ventricular arrhythmia. Multicenter Automatic Defibrillator Implantation Trial Investigators. *N Engl J Med* 1996; 335: 1933-40.
24. Moss AJ, Zareba W, Hall WJ, et al. Prophylactic implantation of a defibrillator in patients with myocardial infarction and reduced ejection fraction. *N Engl J Med*. 2002; 346: 877-83.
25. Kuck KH, Cappato R, Siebels J, Ruppel R for the CASH investigators. Randomized comparison of antiarrhythmic drug therapy with implantable defibrillators in patients resuscitated from cardiac arrest. *Circulation* 2000; 102: 748-54.
26. The Anthiarrhythmics versus Implantable Defibrillators (AVID) Investigators. A comparison of antiarrhythmic drug therapy with implantable defibrillators in patients resuscitated from near-fatal ventricular arrhythmias. *N Engl J Med* 1997; 337: 1576-83.