

The Effect of L-arginine on Neointimal Proliferation and Artery Remodeling on an Iliac Artery Lesion Caused by a Balloon Catheter in Hypercholesterolemic Rabbits

José Knopfholz, Dalton B. Prêcoma, Paulo Roberto S. Brofman, Gabriela Elisete Bier, Ruy Fernando Kuenzer C. da Silva, Anna Paula Kuchnir Silva, Ana Carolina Lemos, Priscila de Oliveira Silva, Jacqueline Domsin de Moraes

Pontifícia Universidade Católica do Paraná - Curitiba, PR - Brazil

Objective: It has been implied that neointimal proliferation and remodeling are the major causes of restenosis. The objective of this study is to assess the effect of orally administered L-arginine on these two factors in hypercholesterolemic rabbits that had suffered an injury to their iliac arteries caused by a catheter balloon.

Methods: The study included nineteen rabbits that were divided in two groups: control (CG) and arginine (AG). There were 19 arteries studied from the control group and 17 in the arginine group. The animals were placed on a 2% hypercholesterolemic diet for 15 days and then submitted to a balloon angioplasty in order to produce a lesion in their iliac arteries. Next, the AG animals were given a 1g/kg/day oral dose of a L-arginine solution. The animals were sacrificed 15 days after the angioplasty procedure and histological artery sections were prepared, stained and fixed. The ratio between the neointimal area (in mm²) and the media layer (in mm²) was used to represent lesion development. In order to determine remodeling, the ratio between the total area of the medial portion of the vessel (greater balloon contact) and the total area of the reference segment of the vessel (less balloon contact) was used.

Results: Mean neointimal thickness (NI/M) was 0.8151 ± 0.2201 in CG and 0.3296 ± 0.1133 in AG. Remodeling patterns for the two groups studied were similar.

Conclusion: In the experimental model used, L-arginine was able to reduce intimal tissue thickness in hypercholesterolemic rabbits but did not act on artery remodeling.

Key words: Restenosis, neointimal proliferation, remodeling, nitric oxide.

The neointimal thickness of a vessel has been given great importance since it is linked to various therapeutic intervention complications. For vein grafts inserted into arterial circulation this factor is implicated as the genesis for postoperative recurrent occlusions¹. In vasculopathies related to heart transplants, it has been proven that this phenomenon plays a decisive role². Restenosis after an angioplasty and stent implantation procedures is almost exclusively explained by neointimal hyperplasia³.

Neointimal formation is different from atherosclerotic plaque which is basically formed by smooth muscle cells and an extracellular matrix. These cells migrate from the media layer to the intimal layer during different stages of this phenomenon⁴. This process could be inhibited by mechanisms mediated by nitric oxide (NO)⁵. More profound

knowledge regarding the stimulating and limiting factors of neointimal growth is needed and, in this context, the nitric oxide precursors could have a role in the intervention of this process.

A few studies have been conducted with L-arginine, the precursor of nitric oxide, that in addition to an accessible cost is well tolerated and commercially available⁶. There is however some divergence in the studies published, but the benefits have been well established when the drug is injected locally (intravenously)^{7,8}. It is worth noting that experimental research has concluded that physical exercise increases nitric oxide vascular expression and reduces neointimal hyperplasia and platelet adhesion after angioplasty and stenting procedures in rats⁹.

Methods

Before the experiment was conducted it was approved by the Animal Research Ethics Committee.

The study included nineteen male New Zealand albino rabbits (*Oryctolagus cuniculus*) obtained from the vivarium of the Pontifical Catholic University in the state of Parana with a mean age of six months that were divided into two groups: control group (CG) (n=10) and arginine group (AG) (n=9). For the purposes of the variables in this study two arteries were chosen in each rabbit and were considered as independent observations. As such the analysis was based on the results obtained from 19 arteries in the control group (1 artery was lost due to technical problems) and 17 arteries in the arginine group (1 artery was lost due to technical problems).

The animals were fed a hypercholesterolemic diet. The 2% hypercholesterolemic diet was prepared by dissolving 200g of cholesterol (Sigma-Aldrich®) in 800 milliliters (ml) of chloroform (Biotec®) and distributing the solution in 10 kilograms (kg) of Nuvital® animal feed. The dissolved cholesterol was distributed using a spray gun over the feed which was placed in a flat and shallow dish. After the 24 hours required for adequate evaporation of the chloroform the feed was distributed to the animals. This diet was fed to the animals for fifteen days before the procedure to induce the arterial lesion and continued up to the day that the animals were sacrificed.

The rabbits were anesthetized with a 5mg/kg dose of Xylazine (Coopazine®-Coopers) and a 3.5mg/kg dose of Ketamine (Vetanarcol® König) injected in the thigh muscle. A blood sample was then drawn to measure total cholesterol. After anesthetic induction, a trichotomy was performed in the lower abdomen and groin followed by an aseptic and antiseptic cleaning of the area. Next, a 2 to 3cm longitudinal incision was made in the groin skinfold to expose the left and right femoral arteries which were repaired with 3-0 cotton thread. Next a small cross-sectional arteriotomy was performed and a 0.014 metal guide wire was inserted through which a 3.0 mm diameter balloon catheter with a length of 20 mm was entered (balloon/artery radius of 2.5:1) and inserted in the lumen of the right iliac artery (RIA) and left iliac artery (LIA). The balloon catheter was inflated for five minutes in each artery at a pressure of 5 atm. causing the artery wall to expand. After the balloon was deflated, the arteries were ligated immediately above the balloon catheter entrance orifice with 3-0 cotton thread to contain blood flow. Lastly, the skin was closed with Vicryl 3-0 sutures. Analgesics and antibiotics were administered to both groups.

Twenty-four hours after inducing the artery injury, the arginine group began receiving a 1g/kg/day dose of L-arginine. This substance was administered in the form of a solution that had been previously homogenized with a concentration of 3g/10 ml of solution. This was drawn using a graduated syringe and administered in the animal's oral cavity by slowly pressing the plunger ensuring that none of the solution was lost. During this procedure the rabbit was confined in a box with an adequate opening for its head that limited its movements and facilitated the acceptance

of the drug.

On the 15th day after the artery injury, each animal was weighed and anesthetized once again and after antiseptic procedures and placement of sterile fields, a longitudinal incision was made that extended from the thoracoabdominal transition to the pelvic region and then extended to the right and left groin regions. The femoral, iliac and aorta arteries were exposed and observed. After the animals were sacrificed using a lethal dose of barbiturates, the arteries were cleaned and fixed with 10% phosphate buffered formaldehyde solution (pH=7.6) for 10 minutes. Next the block enveloping part of the aorta and iliac arteries was removed. For identification the RIA was stored with a stitch in the distal portion.

For histological and morphometric analysis the artery specimens, consisting of the distal segment of the aorta up to the iliac arteries, were fixed in formalin for 24 hours and processed for the making of the histological sections. Cross sectional slices of the arteries were cut with a thickness of 2 to 3 mm each. The samples were placed in identified histological containers, separating the medial segment which had greater contact with the balloon from the reference segment (distal and proximal to the balloon). The samples were identified by the number of the rabbit and the side of the iliac artery in one of the extremities of the slide followed by the register of the section location.

The following variables were used for morphometric and remodeling analysis: neointimal area, media layer area and total vessel area expressed in mm². The intimal thickness was evaluated using the ratio between the neointimal area and the media layer area, so that the size of the artery to be analyzed could be considered. Therefore in order to assess the development of the lesion, the neointimal area was compared to the size of each vessel or in other words the percentage of neointimal tissue in relation to the media layer area was measured. In order to determine remodeling, the ratio between the total area of the medial portion of the vessel and the total area of the reference segment of the vessel expressed as a percentage was used. This was considered positive when the relative medial segment area (of interest) was 10% greater than the reference segment area and negative when the medial segment area was 10% less than the reference segment area.

The results of the variables NI/M, vessel area and remodeling were expressed as averages and standard deviations while the results of the variable remodeling pattern were expressed as frequencies and percentages. To compare the two groups: control and arginine in relation to the averages of the variables NI/M, vessel area and remodeling, the Student's t-test was used for the independent samples, considering the homogeneity of the variations. To compare the medial and reference locations within each group, the Student's t-test was used for paired samples. Normality was verified using the Shapiro-Wilks test. In the cases of non-normality a logarithmic transformation was applied to the data. To compare the groups in relation to remodeling type distribution the chi-square test was used. For all tests statistical significance was considered as $p < 0.05$.

Results

Animal weight and cholesterol dosage- Animal weights before the start of the diet and on the day they were sacrificed are shown in table 1. There was no statistical difference between the control group and the arginine group. The cholesterol levels of the samples collected at the time of the balloon injury were statistically similar and elevated in both groups as shown in table 1.

Intimal tissue thickness - The comparison of the degree of intimal tissue growth between the control group and the arginine group is shown in table 2. There was a significant difference between the group that received the study drug and the group that did not. An artery section from both groups is shown in figure 1.

Remodeling patterns - The results are shown in table 3.

Discussion

The inhibition of neointimal formation has been targeted as the solution for restenosis in the post stent era. The notable statistical difference detected in this study suggests that L-arginine is able to inhibit neointimal proliferation in the experimental model in question. These results are similar to those found by Le Tourneau et al¹⁰, in an experiment with hypercholesterolemic rabbits.

Some studies of L-arginine in humans have not demonstrated favorable effects on restenosis rates. Dudek et al^{11,12} initially administered the drug intravenously followed by an oral dose

of 6 g/day for 14 days after the angioplasty. Despite the fact that re-obstruction rates and neointimal proliferation were similar, this is a much lower dose than that used in this study. Even though it is not possible to extrapolate the experimental dose for humans, studies have demonstrated that this aminoacid can safely be prescribed in doses of 12 g/day¹³. However, there is limited medical literature on the oral use of L-arginine in humans. Based on this study it is believed that the issue may be reconsidered.

The physiopathogenic basis of the relationship between nitric oxide and remodeling could be the inhibition of intimal thickness, the production of metalloproteinase and the apoptosis of smooth muscle cells⁵. The activation of the metalloproteinase matrix is required for adaptive artery remodeling to occur and NO is one of the factors that is able to stimulate this production since it is able to regulate their expression as well as mediate the metalloproteinase inhibiting factors. An ex-vivo study suggested that nitric oxide deficiencies alter the homeostasis between the forming and inhibiting factors, promoting the degeneration of the extracellular matrix¹⁴.

Despite the great reduction of neointimal thickness obtained in this study, remodeling patterns were similar. The explanation for this is that the resources of the experimental model used are limited for the study of this phenomenon. The use of arteries without fixing the systemic pressure has been indicated as a method that overestimates the real values of this factor¹⁵. Additionally, tissue retraction after the sacrifice could lead to remodeling dimensional errors.

Variable	Control Group (n=10)	Arginine Group (n=9)	p Value
	Average ±sd	Average ±sd	
Weight 1 (g)	2,480.00 ± 477.96	2,466.67 ± 526.78	0.9545
Weight 2 (g)	2,750.00 ± 344.00	2,644.44 ± 415.67	0.5528
Cholesterol (mg/dL)	1,255.50 ± 207.59	1,242.89 ± 234.58	0.9025

Weight 1 = animal weight before starting the diet; Weight 2 = animal weight on the day they were sacrificed; Cholesterol = total cholesterol dosage.

Table 1– Animal Weight and Cholesterol Dosage

Variable	Control Arteries (n=19)	Arginine Arteries (n=17)	p Value
	Average ± sd	Average ± sd	
NI (mm ²)	0.33±0.19	0.17±0.09	0.0000
M (mm ²)	0.42±0.22	0.56±0.36	NS
NI/M	0.8151 ± 0.2201	0.3296 ± 0.1133	0.0000
NI/M medial	0.6969 ± 0.4107	0.2764 ± 0.1392	0.0004
NI/M reference	0.8655 ± 0.2189	0.3556 ± 0.1357	0.0000

NI = Neointimal area; M = media layer area; NS = no significance; NI/M = mean neointimal thickness = ratio of the neointimal area and the media layer area.; NI/M medial = ratio of the neointimal area and media layer area in the medial artery segment; NI/M reference = ratio of the neointimal area and the media layer area in the reference artery segment.

Table 2 – Intimal tissue thickness (comparison between the control group and the arginine group)

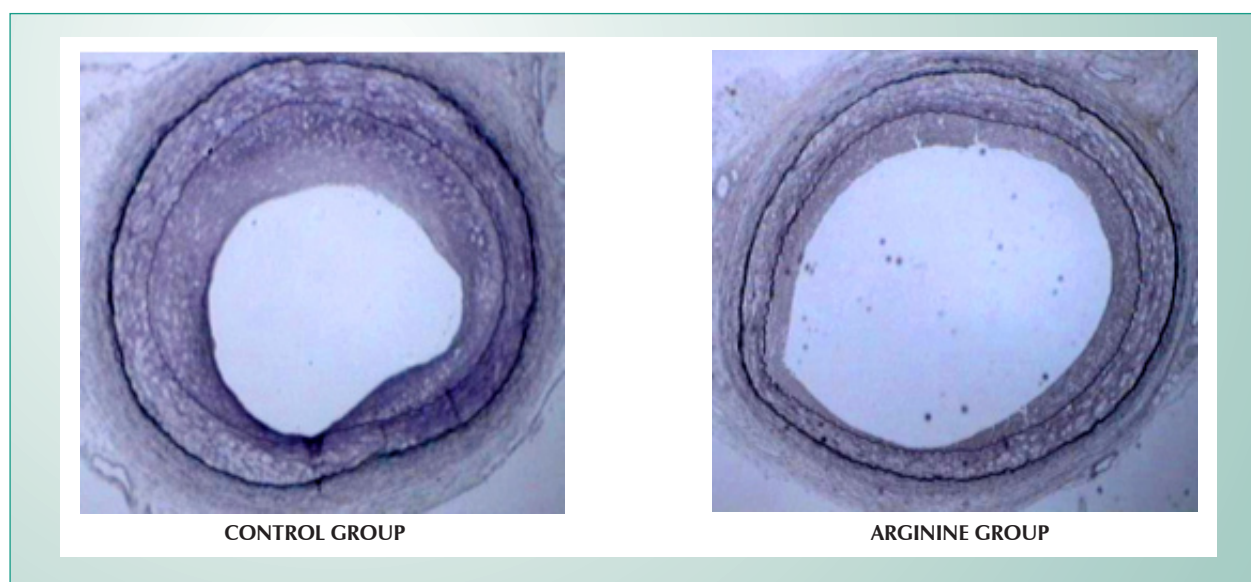


Fig. 1 - Artery Sections from the control group and the arginine group.

Remodeling Pattern	Control Arteries	Arginine Arteries
Positive	9 (47.37%)	6 (35.29%)
Indifferent	6 (31.58%)	5 (29.41%)
Negative	4 (21.05%)	6 (35.29%)
Total	19	17

The result of the statistical test indicated similar remodeling between the groups using a significance level of 5% ($p=0.6118$).

Table 3 – Remodeling Patterns in the Control Group and the Arginine Group

In one of the few studies on the subject, Le Tourneau et al¹⁰ noted the absence of favorable remodeling (vessel enlargement) in the group of animals treated with L-arginine, a fact that did not occur in the control group. Therefore, these authors suggested that this drug could have an inhibiting effect on favorable remodeling. In this study, the animals were sacrificed after four weeks. This could signify that the action of nitric oxide on remodeling takes place between 2 and 4 weeks after the angioplasty. Nevertheless it is important to note some differences between this study and the study conducted by Le Tourneau. In the Le Tourneau's study, the L-arginine was added to the animals' water which is considered inefficient since there is no control over the adequate intake of the aminoacid or the actual dosage. Additionally, in the Le Tourneau et al¹⁰ study, the lesion was developed during the initial stage using a Fogarty catheter and the angioplasty was performed 6 weeks after this procedure¹⁶. Therefore, the experimental model was different. Lastly, in the present study, the average of the artery sections that had contact with the balloon was used for histological analysis. In the Le Tourneau's study, only the

section with the smallest luminal diameter was considered, a fact that could increase the margin of error.

Based on the facts presented, the possibility that the role of L-arginine is to prevent neointimal thickening appears at a time when normal endothelial function is gaining importance since endothelial disease, in general, is responsible for heart disease in general. Regardless of the therapeutic aspect, the results of this study emphasize the role of nitric oxide in neointimal formation and prove that a better knowledge of the physiopathology of this phenomenon is required. Therefore the relevance of L-arginine could be perfected, improved or even substituted provided that the mechanisms which inhibit neointimal growth are understood.

The results of this study differ from those published in medical literature to date, since L-arginine had a positive effect on neointimal proliferation and a neutral effect on remodeling. Considering its low toxicity, this drug could be an isolated option or used in combination with other inhibition strategies for neointimal formation. Further studies will be required to determine these possibilities as well as other new therapeutic strategies.

From this study it is possible to conclude that in the experimental model used, L-arginine was able to reduce neointimal proliferation in hypercholesterolemic rabbits but did not affect artery remodelling¹⁷.

Acknowledgements

We would like to thank Prof. Dr. João Carlos Repka for his valuable contribution.

Potencial Conflict of Interest

No potential conflict of interest relevant to this article was reported.

References

1. Fulton GJ, Davies MG, Barber L, Gray JL, Svendsen E, Hagen PO. Local effects of nitric oxide supplementation and suppression in the development of intimal hyperplasia in experimental vein grafts. *Eur J Vasc Endovasc Surg* 1998; 15: 279-89.
2. Perrault LP, Malo O, Bidouard JP, Villeneuve N, Vilaine JP, Vanhoutte PM. Inhibiting the NO pathway with intracoronary L-NAME infusion increases endothelial dysfunction and intimal hyperplasia after heart transplantation. *J Heart Lung Transplant* 2003; 22: 439-51.
3. Mintz G, Popma JJ, Richard AD. Arterial remodeling after coronary angioplasty: a serial intravascular ultrasound study. *Circulation* 1996; 94: 35-43.
4. Schwartz SM, deBlois D, O'Brien ER. The intima. Soil for atherosclerosis and restenosis. *Circ Res* 1995; 77: 445-65.
5. Ignarro L. Biological actions and properties of endothelium-derived nitric oxide formed and released from artery and vein. *Circ Res* 1989; 65: 1-21.
6. Chan AW, Chew DP, Lincoff M. Update on Pharmacology for Restenosis. *Current Int Card Rep* 2001; 3: 149-55.
7. Kalinowski M, Alfke H, Bergen S, Klose KJ, Barry JJ, Wagner HJ. Comparative trial of local pharmacotherapy with L-arginine, r-hirudin, and molsidomine to reduce restenosis after balloon angioplasty of stenotic rabbit iliac arteries. *Radiology* 2000; 219: 716-20.
8. Niebauer J, Schwarzacher SP, Hayase M, et al. Local L-arginine delivery after balloon angioplasty reduces monocyte binding and induces apoptosis. *Circulation* 1999; 100: 1830-5.
9. Indolfi C, Torella D, Coppola C, et al. Physical training increases eNOS vascular expression and activity and reduces restenosis after balloon angioplasty or arterial stenting in rats. *Circ Res* 2002; 91: 1190-7.
10. Le Tourneau T, Van Belle E, Corseaux D, et al. Role of nitric oxide in restenosis after experimental balloon angioplasty in the hypercholesterolemic rabbit: effects on neo-intimal hyperplasia and vascular remodeling. *J Am Coll Cardiol* 1999; 33: 876-82.
11. Dudek D, Heba G, Bartus S, et al. Effects of L-arginine supplementation on endothelial function after stent implantation. *Kardiol Pol* 2002; 57: 389-97.
12. Dudek D, Legutko J, Heba G, et al. L-Arginine supplementation does not inhibit neo-intimal formation after coronary stenting in human beings: an intravascular ultrasound study. *Am Heart J* 2004; 147: E12.
13. West SG, Likos-Krick A, Brown P, Mariotti F. Oral L-arginine improves hemodynamic responses to stress and reduces plasma homocysteine in hypercholesterolemic men. *J Nutr* 2005; 212-7.
14. Eagleton MJ, Peterson DA, Sullivan VV, et al. Nitric oxide inhibition increases aortic wall matrix metalloproteinase-9 expression. *J Surg Res* 2002; 104: 15-21.
15. Kobs RW, Muvarak NE, Eickhoff JC, Chesler NC. Linked mechanical and biological aspects of remodeling in mouse pulmonary arteries with hypoxia-induced hypertension. *Am J Physiol Heart Circ Physiol* 2005; 288: 1209-17.
16. Wilensky RL, March KL, Gradus-Pizlo I, et al. Vascular injury, repair, and restenosis after percutaneous transluminal angioplasty in the atherosclerotic rabbit. *Circulation* 1995; 92: 2995-3005.
17. Haarer SL, Emig LL, Keiser JA. Vascular remodeling in balloon injured rabbit iliac arteries. *Basic Res Cardiol* 1998; 93: 210-7.