

## Case 3/2006 – Nineteen-month-old Infant with Pulmonary Atresia and Ventricular Septal Defect and Decreased Pulmonary Blood Flow

Edmar Atik

Instituto do Coração do Hospital das Clínicas da FMUSP - São Paulo-SP - Brazil

### Clinical findings

Nineteen-month-old white male infant presenting with progressive cyanosis since birth. Dyspnea on minimum exertion was observed. Physical examination revealed respiratory distress, severe cyanosis, normal pulses, 45% oxygen saturation, weight of 8900 g, heart rate of 145 bpm, and blood pressure of 90/65 mmHg. The aorta was not palpable. No deformities were observed in the precordium, and the apical impulse was not palpable. Heart sounds were accentuated and a grade 1-2/6 blowing continuous murmur in the aortic area and in the right side of the posterior chest was observed. The liver was not palpable.

The electrocardiogram showed signs of right ventricular overload, with a positive T wave in V1 and isoelectric in V6. SÂP: +40°, SÂQRS: +130°, SÂT: +30°.

### Radiograph imaging

The image shows a close-to-normal cardiac silhouette with an upwardly displaced apex, excavated middle arch, widened pedicle and reduced pulmonary vascularity, especially in the periphery and left side (Fig. 1).

### Diagnostic impression

This image suggests a heart disease like the tetralogy of Fallot and the difference in the vasculature strongly suggests associated left pulmonary artery stenosis or pulmonary atresia with ventricular septal defect with systemic-to-pulmonary collateral vessels more prominent in one side, the right side in this case.

### Differential diagnosis

Heart diseases similar to the tetralogy of Fallot, such as the double outlet right ventricle, single right ventricle, tricuspid and mitral atresia, all accompanied by pulmonary stenosis should be considered.

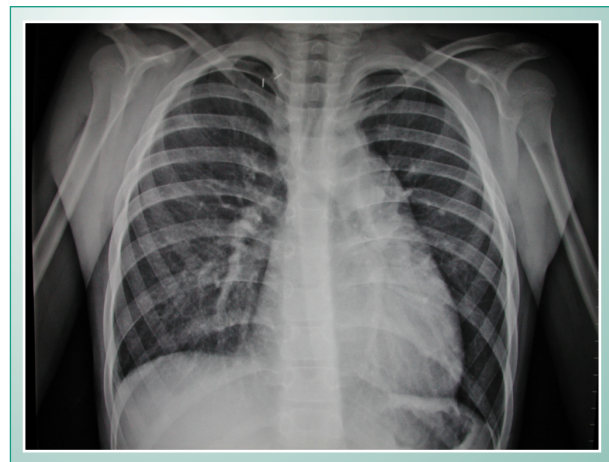
### Diagnostic confirmation

Severe cyanosis with continuous heart murmur and right ventricular overload in the electrocardiogram suggest a heart disease of the pulmonary atresia type, with ventricular septal defect and systemic-to-pulmonary collateral vessels, more prominent in the right side in this case. The echocardiogram confirmed the diagnosis, and the pulmonary arteries were

not visualized. Cardiac catheterization showed systemic-to-pulmonary vessels at the right side with severe stenoses towards the upper and lower lobar arteries. Left retrograde venography showed an exiguous pulmonary tree in all lobes. The pulmonary arteries were not visualized. .

### Management

A left Blalock-Taussig anastomosis at the hilum had been planned as the first step, followed by a right anastomosis with unification of the two contiguous collaterals. However, during the anesthetic induction the patient presented with increased hypoxia, shock, cardiac arrest and death.



**Fig. 1** – Chest radiograph shows the signs normally found in the tetralogy of Fallot with reduced pulmonary vasculature, excavated middle arch, and upwardly displaced apex. In pulmonary atresia with ventricular septal defect and systemic-to-pulmonary vessels of reduced diameter, the same image can be observed.